

---

# Interpreting the Cone Beam Data Volume for Occult Pathology

*Dale A. Miles*

Although digital x-ray adoption has been slow over the 20 years since its introduction, cone beam volumetric imaging (CBVI) or cone beam volumetric tomography (CBVT) has been employed very rapidly. Dentists will not replace all panoramic or intraoral procedures with CBVT, but the images and image data produced by this modality will help dentists perform many dental tasks more efficiently and confidently, tasks such as implant site assessment, visualizing temporomandibular joint structures and impaction problems among others. In short, dentistry, like medicine, will select the appropriate imaging modality for a specific diagnostic task—instead of trying to make one modality fit all tasks. Images and data sets will be moved between clinicians and laboratories rapidly and efficiently for diagnosis, second opinion, and even model and surgical guide construction as well as orthodontic models. Orthodontic analyses will eventually be performed with more accuracy in three-dimensional (3D) and 4D formats. This article attempts to predict in a limited way some of the imaging “standards of care” that will arise from the latest advancements in imaging and inform the reader of some issues yet to be resolved. (Semin Orthod 2009;15:70-76.) © 2009 Published by Elsevier Inc.

With the advent of the radiology technology called cone beam computed tomography imaging, dentistry has leapt forward in its diagnostic capability. Visualization of anatomy and pathology has now replaced radiographic interpretation. Dentists and dental specialists now have an imaging modality that rivals that of their medical colleagues. Where we once looked at “Rorschach tests,” which we called plain film radiographs, we now can look at two-dimensional (2D) and 3D color reconstructions of the region of interest which we need to consider in our diagnosis.

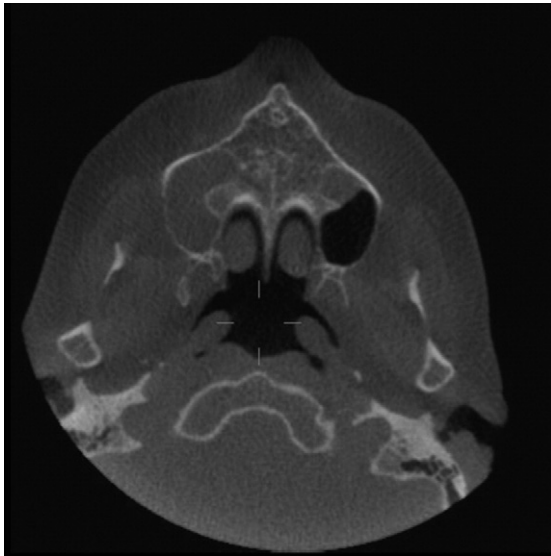
With this dramatic improvement in imaging capability comes the obligation to look at much more clinical radiographic data to avoid missing a significant finding in what is termed the data volume. The data volume, which consists of the information that is acquired during the image acquisition process, can range in size for each patient from 99 MB to 250 MB of data. When we refer to the data volume, we are really referring to the myriad of slices obtained during the scan. Unlike looking at a single panoramic or supplementary radiograph, the clinician must now scroll through slices that can number over 500 in three separate planes of section, namely, axial, sagittal, and coronal. The dentist or dental specialist cannot abrogate this responsibility just by selectively looking at a region of interest such as an implant site. The entire data volume must be scanned and interpreted for reportable findings and occult pathology. This obligation extends also to the laboratory service or cone beam owner as well as the referring clinician. Both the owner of the image acquisition site and the clinician requesting the scan would be held ac-

---

*Adjunct Faculty, University of Texas School of Dentistry at San Antonio, San Antonio, TX; Adjunct Faculty, Arizona School of Dentistry & Oral Health, Mesa, AZ; and Private Practice, Digital Radiographic Solutions, Oral and Maxillofacial Radiology, Fountain Hills, AZ.*

*Address correspondence to: Dale A. Miles BA, DDS MS, FRCD(C), 16426 E Emerald Dr., Fountain Hills, AZ 85268. E-mail: edts@cox.net*

© 2009 Published by Elsevier Inc.  
1073-8746/09/1501-0\$30.00/0  
doi:10.1053/j.sodo.2008.09.009



**Figure 1.** An axial view showing mucosal change filling the right antrum entirely, and left partially at the level of the nasopalatine foramen. Other axial slices and additional views in other planes of section will completely characterize the changes, radiographically.

countable for a significant missed finding should the patient be harmed.<sup>1</sup>

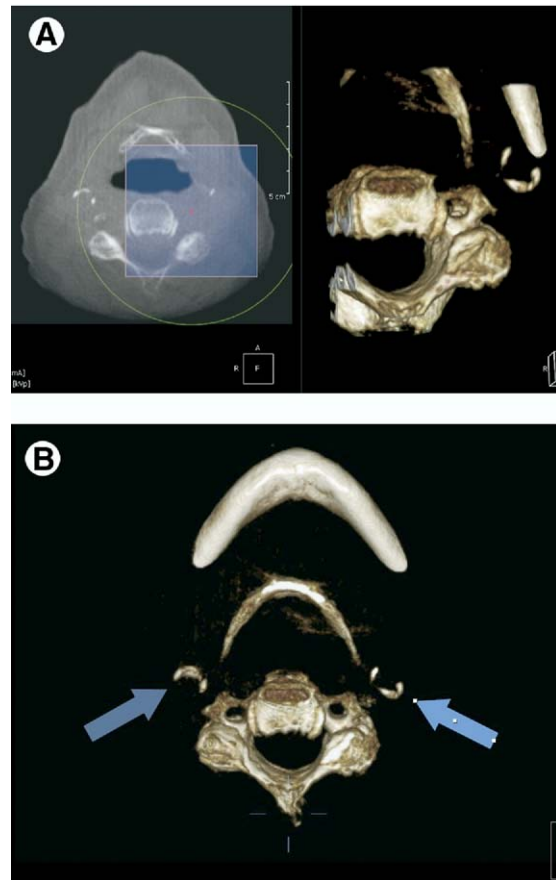
### Occult Pathology

When a volume is acquired, there is usually a prescribed reason for the dentist to order the “scan.” Implant site evaluation, orthodontic assessment, presurgical evaluation of an impacted third molar . . . all of these tasks (and many more) will eventually be routinely performed by CBVT (cone beam volumetric tomography). Specific data and images, produced by the scanner owner, are used by the referring clinician in an analysis to manage a patient’s problem or disease. However, in many cases, there are other findings that are “reportable” that could also affect the patient or their dental treatment. These findings, such as a sinus blockage, a calcified plaque, osteoarthritic changes in the vertebral bodies or temporomandibular joint (TMJ) condyle, or even a tumor, were not anticipated or suggested by clinical examination or the medical history. These findings are termed “occult”; that is, they are unanticipated and possibly harmful to the patient.

At the very least, occult findings can alter the treatment plan in many situations, requiring the

referring clinician to postpone their anticipated dental treatment to refer the patient to the primary care physician or medical specialist to evaluate and/or manage the finding before the dental treatment can resume. An example might be a pan-sinusitis in an implant patient (Fig 1). If the implant is to be placed in the maxilla and a sinus augmentation procedure anticipated, the paranasal sinuses need to have a “clean bill of health” before the surgery is planned.

At the other end of this spectrum of findings are problems that could affect the patient’s life. These findings do occur, and will no doubt increase in incidence as the adoption of CBVT



**Figure 2.** (A) Bilateral “circumferential” calcifications consistent with MAC (medial arterial sclerosis). The three-dimensional (3D) color reconstruction is of the patient’s left side where the red “x” is located. Image was created in OnDemand3D (CyberMed International, Seoul, Korea) using their “Cube” tool. (B) 3D color reconstruction showing “ring-like” calcifications bilaterally. (Color version of figure is available online.)

moves ahead. An example here is the finding of concentric or ring-like calcifications in a diabetic patient (Fig 2). These calcifications, called MAC (medial arterial sclerosis) signal a patient in or nearing ESRD (end stage renal disease), a condition that often leads to below-the-knee amputations in this diabetic population.<sup>2,3</sup>

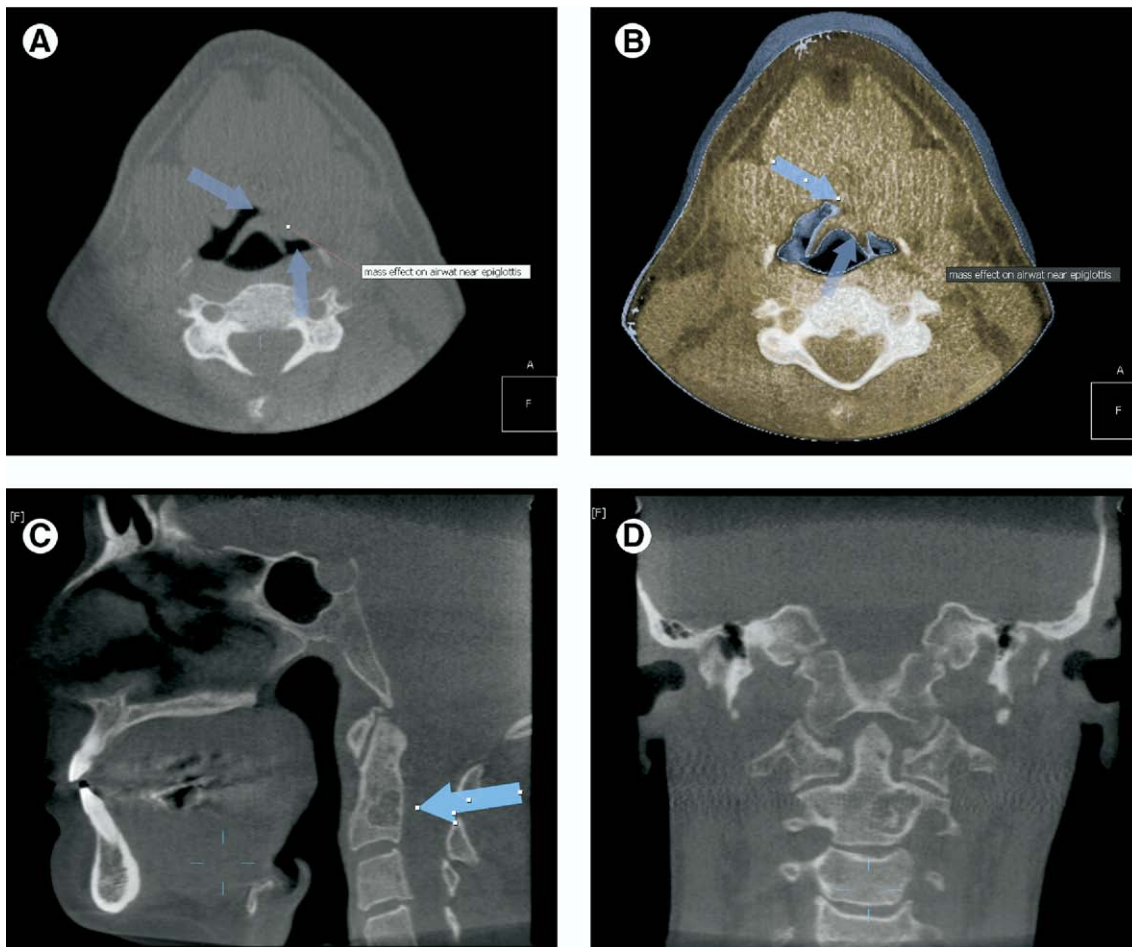
### Some Common Findings

A recent study reported the “reportable findings” in the first 380 cases I reviewed for multiple scanning sites.<sup>4</sup> Among these reportable findings were: congenitally missing teeth, calcified, elongated stylohyoid process(es), calcified lymph nodes, retained root(s), metallic frag-

ments, hypoplasias/hyperplasias (facial, TMJ, and teeth), medial sigmoid depression(s), dilacerated roots, tori, enostosis, SSGD (submandibular salivary gland depression), fibrous healing defect, and so forth.

“Boney” conditions reported in these patients included: numerous cases of “apical periodontitis” (not seen in the conventional images), residual cysts, furcation problems, recent extraction site(s), unanticipated impacted teeth, idiopathic osteosclerosis, and so on.

Significant “occult” findings included: one suspected case of Paget’s disease of bone, several implants impinging in anatomic spaces, 2 pharyngeal masses, 2 cases of a blocked ostium, several antral lesions, a suspected neurolem-



**Figure 3.** (A) Two-dimensional (2D), thin slice (0.15 mm) axial view from data showing a “mass effect” on the left pharyngeal tissues encroaching on the epiglottis. (B) A thickened “slice” (20 mm) 3D color reconstruction of the same “mass.” (C) A small multilocular lesion in vertebral body C-2 (odontoid process) suggestive of a “simple bone cyst” or “aneurysmal bone cyst.” (D) Coronal view of lesion in (c). (Color version of figure is available online.)

moma in the inferior alveolar canal, an undiagnosed fractured zygoma, and numerous vertebral changes including 2 surgical “repairs” of vertebrae. Figure 3(a) and (b) represent an example of a “mass” in the throat. Figure 3(c) and (d) show a vertebral body lesion that the patient and the doctor were not aware of—true “occult” pathology that will significantly impact the patient.

The differential diagnosis for the lesion seen in Fig 3(c) and (d) included:

1. Simple bone cyst
2. Aneurysmal bone cyst
3. Giant cell tumor

The inclusion of the vascular lesion mandated an aspirational biopsy and follow-up with computed tomographic (CT) and magnetic resonance (MR) imaging with and without contrast agent. The patient had been referred for a single dental implant site evaluation.

### Some Findings of Significance

Oral and maxillofacial radiologists receive training in many imaging modalities and pathologic conditions in the head and neck region, other than the dental bases. There are stored references for medical conditions that occur with some frequency in these scans to add at the end of an interpretive report as reference material for educating the dentist as to the “severity” of the finding and the need for referral—in some cases, immediately. Oral and maxillofacial radiologists also make specific referral and management recommendations when indicated by the radiographic findings.

The following are conditions seen sufficiently frequently to require IMMEDIATE referral recommendations:

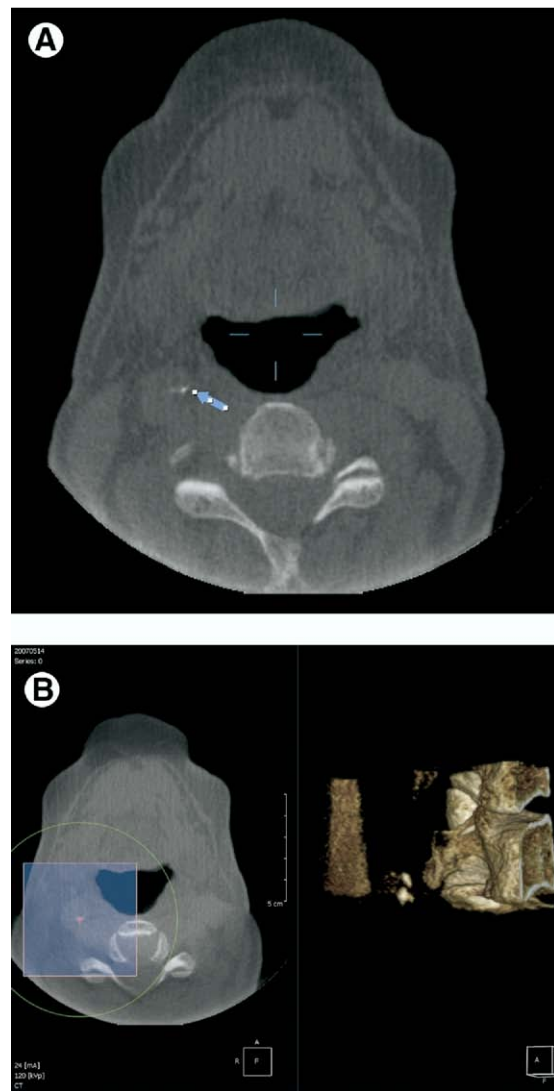
1. Calcified carotid plaques (Fig 4)
2. MAC—Monckeberg’s calcinosis
3. Paranasal sinus disease (Fig 5)
4. Suspected mucocele (Fig 6)
5. “Floating tooth” (Fig 7)

All of these conditions have significant morbidity associated with their presence and their management. Most of these also result in death or a significant change in the patient’s “quality of life.”

**Calcified carotid plaques.** It is well documented now that patients who have the dif-

fuse, irregularly shaped sclerotic plaques seen in the oropharyngeal airway on panoramic radiographs (and now with more clarity on CBVT) have a significant risk of hypertension and stroke.<sup>5</sup>

**Medial arterial sclerosis.** Probably more significantly, these calcifications are now very well-known predictors of early stage renal disease (ERSD), secondary to renal compromise. These patients will lose limbs if aggressive treatment is not instituted as soon as the calcifications are found.<sup>2,3</sup> Worldwide, diabetes mellitus will affect 300 million people by the



**Figure 4.** Two small calcifications in the left carotid region suggestive of sclerotic plaques. (Color version of figure is available online.)

year 2025.<sup>6</sup> The images above in Fig 2 show these lesions.

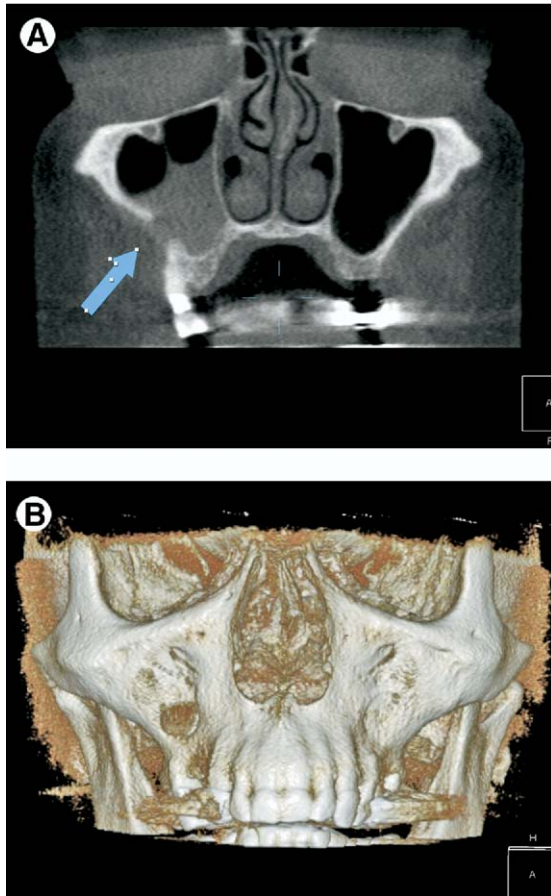
**Paranasal sinus disease.** Sinus problems due to infections and allergies are ubiquitous throughout North America. While most true paranasal sinus problems can be managed with antibiotics and antihistamines, some sinus problems masquerade as inflammatory changes or infections. In reality, unless one examines these spaces closely and can recognize the radiographic features of more ominous problems like the mucocele or intrinsic or extrinsic sinus tumors, significant disorders of these sinus spaces will be missed.

**Mucocele.** Mucoceles of the paranasal sinuses are chronic, cystic lesions, lined by respiratory epithelium formed as the result of blockage of the sinus ostium. The secretions produced can produce an expanding mass that, in turn, can erode or remodel sinus walls. While the contents of the mucocele are usually sterile they can become infected and form a mucopyocele.

**“Floating tooth.”** The differential diagnosis includes

- a. Localized, severe periodontal bone loss
- b. Langerhan’s cell disease

**Figure 5.** Tumor extending from left maxilla to left superior ethmoid air cell region. (Color version of figure is available online.)



**Figure 6.** (A) Lesion in right antrum with perforation of the facial bone (blue arrow). (B) Three-dimensional color reconstruction of the bony perforation (white arrow). This could also be an opening from a Caldwell-Luc procedure since the mucocele is quite uncommon in the maxillary sinuses. The diagnosis of this condition was not known at the time of reporting. (Color version of figure is available online.)

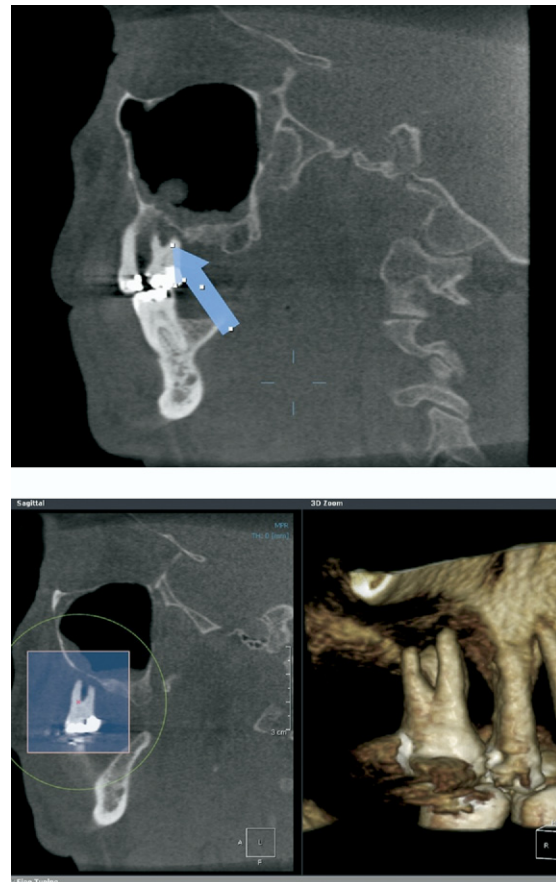c. Lymphoma

d. Various sarcomas (osteo-, chondro-, and fibrosarcoma)

While the majority of localized severe bone loss problems are due to periodontal disease, the differential diagnosis above contains some very significant lesions. Dentists, seeing periodontal disease daily in their practice, can be lulled into making the diagnosis of “bone loss” and possibly miss other subtle changes of the more significant lesions listed.

## The Role of the Oral and Maxillofacial Radiologist (OMFR)

Just as the odontogenic lesions of the dental bases are best interpreted by an oral and maxillofacial pathologist, because of the advanced dental training an oral and maxillofacial radiologist receives, they too are in a better position to review the data sets from CBVT scanners. Medical radiologists are already “overburdened” by the cases produced in the United States, and often the primary read is performed by ex-patriot radiologists living overseas to handle the load of cases. So, for the near future, the oral and maxillofacial radiologist is best suited and available to “read” the data volumes from laboratories and scanner owners such as dentists and dental specialists. Certainly an oral and maxillo-



**Figure 7.** A “floating tooth” in the right maxilla. There was advanced horizontal bone loss in other regions, so the report was of a “clinical impression,” and in this case did not include the differential above. (Color version of figure is available online.)

facial surgeon is also trained to look at conventional CT and MR images, but typically they will not have the time to look at cases referred to their offices if they own scanners. The average, simple case requires 30 to 40 minutes to evaluate the slice data (300-500 slices or more) in each of three planes of section. If the surgeon has 20 to 30 cases per week, this could represent 10 to 25 hours of office time just to sort through patient volumes for potential occult pathology. This does not even account for the analytical reports to be delivered to dentists such as an implant site evaluation. And, remember, the owner of the scanner cannot abrogate this responsibility to the referring dentist. Both clinicians would be held responsible for any significant or reportable finding missed that results in harm to the patient.

### The Current Status of OMFR in the United States

Currently there is enough "radiology talent" in the United States and Canada to report on and manage the cases produced by cone beam owners. There are approximately 140 oral and maxillofacial radiologists (OMFRs), diplomates of the American Board of Oral and Maxillofacial Radiology, and 7 training programs. However, each program offers only between 1 and 4 advanced training positions. Most OMFRs are academically based and read only as a part-time activity. With the growth of CBVT exploding, it will not take long for the volume of cases to exceed the capability of the current "talent pool." More programs in OMFR are needed and more OMFRs and dental school graduates need to consider oral and maxillofacial radiology as a dental profession career choice.

### Questions about the Future of CBVT

Many questions remain to be answered concerning adoption and use(s) of CBVT, qualifications of personnel to perform image acquisition procedures, and licensure of individuals who "read" the scans.

1. How many machine vendors will survive?
2. Who should be allowed to perform the image acquisition?

3. Will it be necessary for all hardware and software to be DICOM compliant?
4. When will that happen?
5. Who should be allowed to perform interpretation of the data volume?
6. Where should they be licensed?
7. How many new OMFR programs/individuals will be necessary to service cone beam owners?
8. When will full Picture Archiving and Communication System/Radiology Information System become available for managing CBVT customers and patient flow?
9. What new software applications will be developed?
10. When will selection criteria for prescribing CBVT be developed?

These are only some of the questions being asked and addressed today in the dental imaging world. Cone beam will not replace intraoral or panoramic imaging techniques for dentistry, but it is clear that the rapid adoption and better clinical decision-making data created by CBVT will ensure its continued use and continual adoption. It is hoped that there will be answers for these questions within the next 5 years of cone beam imaging. (Figure 4 to 7).

### References

1. Holmes SM: i-CAT scanning in the dental office. *Fortress Guardian* 9:2, 2007
2. Dolan NC, Liu K, Criqui MH, Greenland P, Guralnik JM, Chan C, et al: Peripheral artery disease, diabetes and reduced lower extremity functioning. *Diabetes Care* 25: 113-120, 2002
3. Herman WH, Eastman RC: The effects of treatment on the direct costs of diabetes. *Diabetes Care* 21 (Suppl 3): C19-C24, 1998
4. Miles DA: Clinical experience with cone beam volumetric imaging: report of findings in 381 cases. *US Dentistry* 1:39-41, 2006
5. Almog DM, Illig KA, Carter LC, Friedlander AH, Brooks SL, Grimes RM: Diagnosis of non-dental conditions. Carotid artery calcifications on panoramic radiographs identify patients at risk for stroke. *NY State Dental J* 70:20-25, 2004
6. US Department of Health and Human Services, Centers for Disease Control and Prevention: National Diabetes Fact Sheet: National Estimates and General Information on Diabetes in the United States. Atlanta, GA, US Department of Health and Human Services, Centers for Disease Control and Prevention, 1997, pp 1-8