

by Dale A. Miles, DDS, MS, FRCD (C)

Cone Beam 3D— Is It Really for Me?

Introduction

Making clinical decisions with 2D grayscale images is hard. Humans and human structures are not flat; patients are three dimensional. How do we expect to know the truth about the extent of a disease process, or a tooth position and its relation to important anatomic structures, when we're actually guessing at the extent of disease from flat, grayscale images?

Unfortunately, many dentists did not master the intricacies of interpreting X-ray films, phosphor plates, digital images— intraoral or panoramic—even before the advent of cone beam 3D imaging and visualization in 3D color. Do you remember struggling with Clark's rule, tube shift principles, the buccal object rule or the SLOB rule, just to figure out if a mesiodens was on the palatal or the facial?

By the way, the SLOB rule stands for “same on lingual opposite on buccal” and is the simplest way to localize objects on X-rays. It took us 25 years of teaching to figure that one out!

So along comes CBCT (cone beam computed tomography) which, although simple to perform, is quite complex to understand and master¹. And it isn't even computed tomography. The acquisition of the image occurs with one pass around the patient, unlike conventional medical CT which moves the patient lying on a gantry into a scanner at 1mm up to 1cm increments with very high X-ray dose to the patient. Conventional CT detects every “point” in the scan. CBCT detects (captures) only very small cubes, called voxels. This is a partial explanation for why we do *not* get true Hounsfield units in CB 3D/CBCT imaging.

The dose from a conventional medical CT head scan has been calculated at 2,100 microsieverts (μ Sv). The dose from a typical 8cm x 8cm FOV (field of view) Cone Beam 3D scan subjects the patient to only about 17 to 360 microsieverts.²

And unlike conventional medical CT, cone beam 3D imaging is dentally specific. It was made for us! And by the way, we receive 3,600 microsieverts annually just walking around the planet exposed to things like radon, cosmic rays and consumer products. Cone beam 3D imaging, used prudently, is the least of our worries—from the radiation exposure point of view.

So you have to ask yourself the very question posed in the headline of this article: “Is cone beam 3D imaging really for me?” I assure you the answer is a rhetorical and resounding *yes!*

How do you decide?

If you answer *yes* to any or all following questions, cone beam 3D imaging will be invaluable to you.

1. Do you do root canals?
2. Do you perform extractions?
3. Have you struggled with locating the position of the tooth that is impacted?
4. Have you ever had to rule out sinus problems mimicking a toothache?
5. Have you ever had questions about the appearance of a condyle on a panoramic image?
6. Are you planning to place implants surgically?
7. Are you planning to learn about obstructive sleep apnea and how dentists can play an important role and possibly save lives?
8. Have you ever had to take a panoramic to try to determine if a fracture was present in either the maxilla or the mandible?
9. Have you ever struggled to determine whether there was any residual periapical disease present following root-canal therapy by looking at your 2D grayscale images?
10. Do you have to spend \$75,000-\$200,000 to own a machine just to find out if there's a residual periapical lesion on a toothache treated endodontically?

Foiled you! The answer to the last question is actually *no*! You don't have to own a cone beam machine to use the data acquired in the scan. Almost every machine manufacturer provides a "viewing software program" with the machine software so that you can order a cone beam 3D scan and then look at the data burned onto a CD that is sent to you along with the individual data files (DICOM files or .dcm). DICOM stands for digital imaging and communication in medicine—the standard protocol for distributing and sharing patient imaging data.

There are often tools within the software you receive on the CD to do simple tasks such as viewing and measurement. You can also purchase third-party independent software for doing tasks such as implant site assessment and planning, surgical guide construction and the like. In fact, all the images in this article were made using a third-party software called OnDemand3D (Cybermed, Seoul, Korea and Irvine, California).

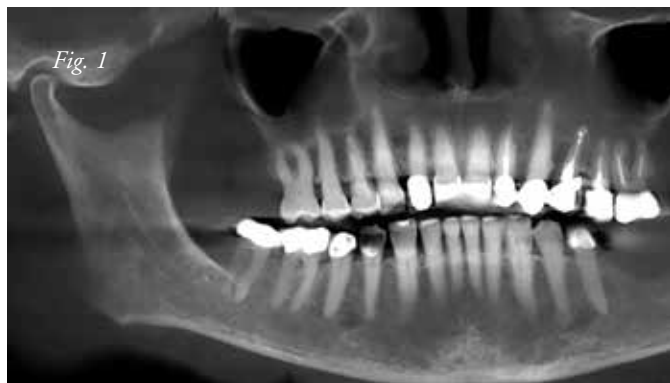So really there is no excuse for you to not use cone beam 3D imaging. However, like any other disruptive technology, the manufacturers sell the machine in the marketplace long before the education about the technology can catch up. You and I both know there's a lot of technology sitting on our shelves which looked exciting at the time of purchase, but after being used a few times, is sometimes relegated to gathering dust. This should not happen with cone beam 3D imaging.

The following are visual examples of cases in which the images obtained by cone beam 3D imaging made the clinical decision simple. There are also cases where unexpected pathology, called occult pathology, was discovered and an important medical referral was made because of the finding's significance. Enjoy the images. It is my bet that you'll soon be using cone beam 3D imaging or will soon purchase a dental cone beam machine to make your dental practice life a whole lot easier and more precise.

Case Presentation

Case 1

A 54-year-old white female was imaged for potential implants in the left posterior mandible. The patient had no chief complaint.



Reconstructed cone beam 3D panoramic image at 25mm. There does not appear to be a lesion on tooth #30. There is a large residual lesion of endodontic origin on tooth #12.

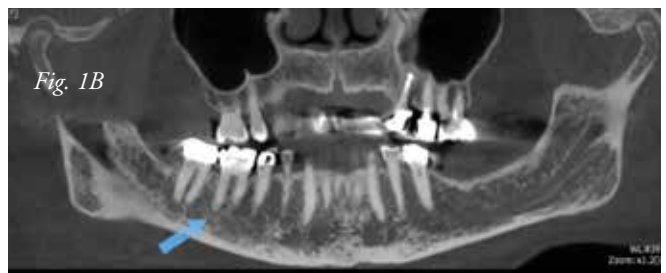

Fig. 1B. In a "thin slice" reconstructed panoramic, the lesion on the distal root of tooth #30 is now visible.

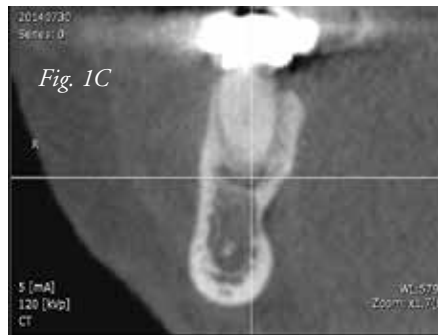
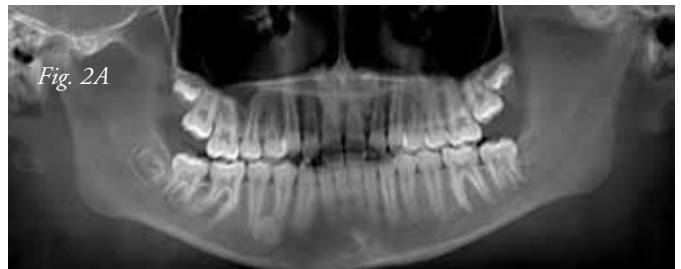
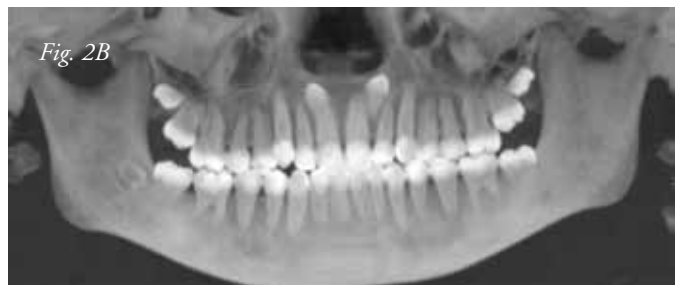Fig. 1C. A thin slice coronal image verifies the lesion. This lesion would not have been seen on a conventional panoramic or periapical image (film or digital).

Case 2

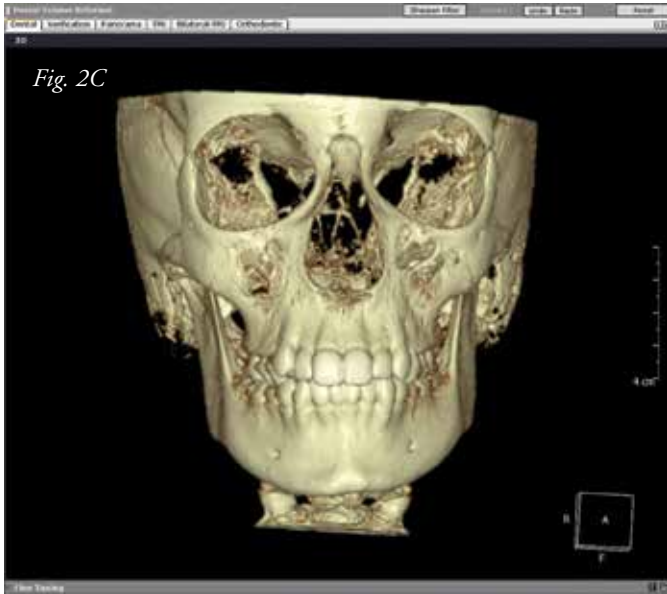
An 11-year-old white female was imaged using cone beam 3D when extra teeth were found on a routine panoramic image.



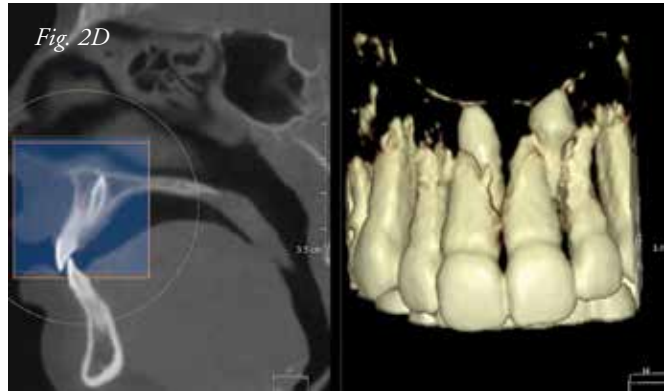
Simulated panoramic shows a ball-shaped "lesion" between the apices of teeth #28 and #29, three of the four third molar follicles, and, if you look closely, blurred tooth-like structures near the apices of the central incisors. The next few images (2B-2D), obtained from the cone beam 3D data, show the power of seeing these hidden structures and localizing them precisely.



A reconstructed MIP (maximum intensity profile) image is used in the cone beam software to delineate the tooth and bone structures. Note the presence of not one but two supernumerary mesiodens in the anterior maxilla, as was suspected by the clinician. MIP images are also great for visualizing calcifications such as carotid plaques, tonsilloliths and physiologic calcifications within the cranial base.



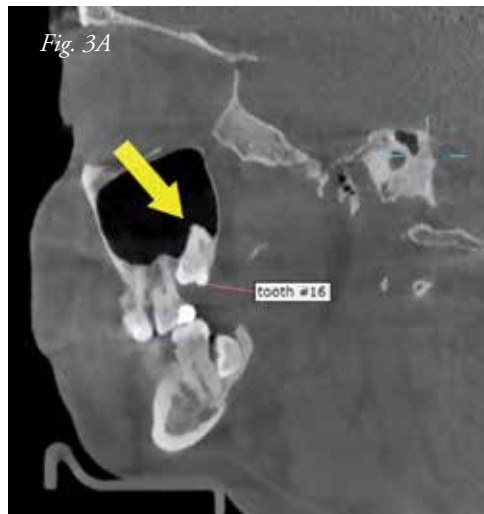A 3D reconstructed view of the entire head was made demonstrating that the mesiodens are not located on the buccal or facial aspect of the arch.



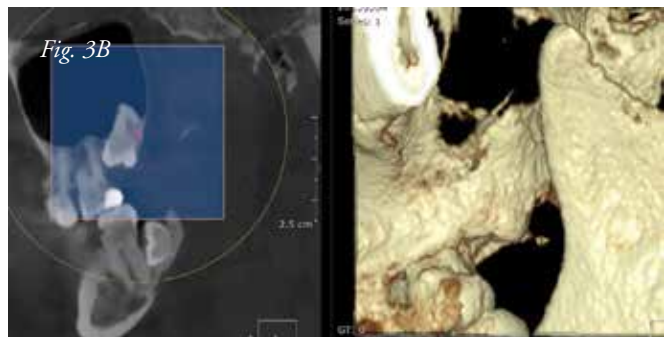
Using a simple tool called a "cube" tool, one of the mesiodens was located on the sagittal image on the left. The cube tool dragged out so the circle included the anterior region bilaterally exposing not one but two supernumerary mesiodens. The software that made these images was OnDemand 3D by CyberMed. (Irvine, California and Seoul, Korea).

Case 3

A 37-year-old female was referred for cone beam imaging because of third molar impactions seen on the panoramic image. No wonder previous dentists she had seen elected to leave her impacted teeth alone. The figures below of impacted tooth #16 illustrate just one of the impaction problems.

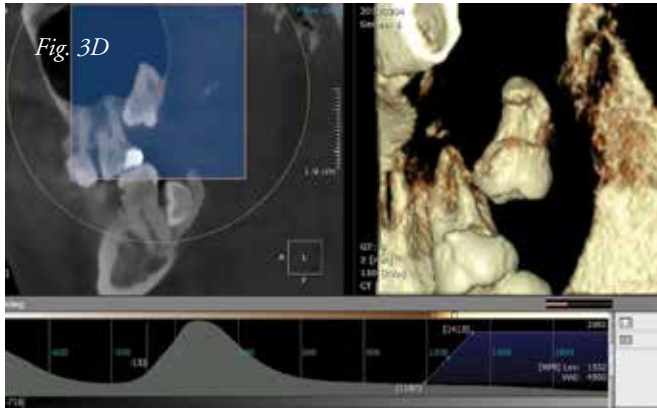


A thin slice (0.1mm) 2D grayscale sagittal image of tooth #16 suggesting a root problem.

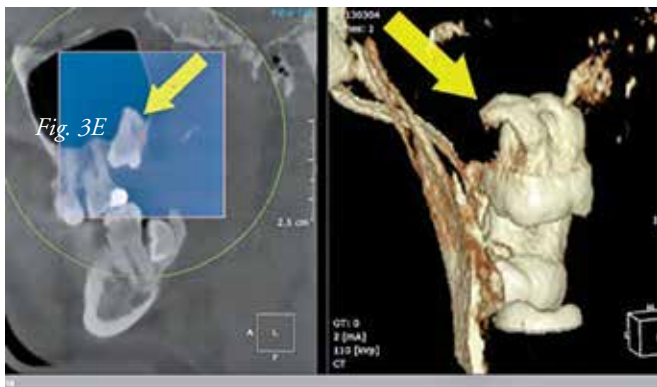


3D color reconstruction of the area to show the overlying bone.

1/4 pg



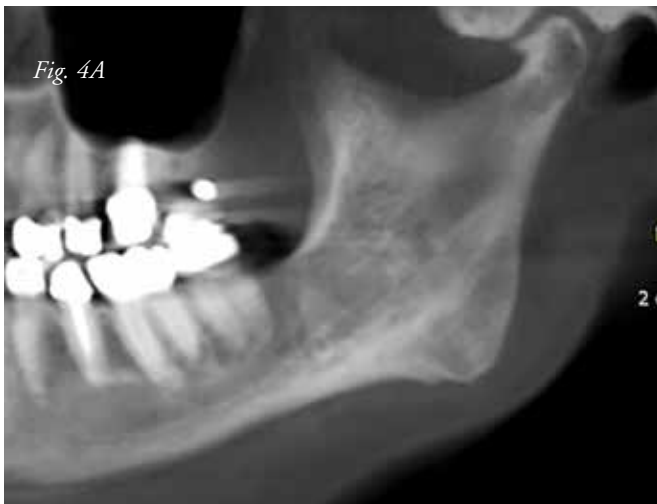Using image processing in the OnDemand 3D software we can "strip away" the overlying bone to show the dilacerated root.



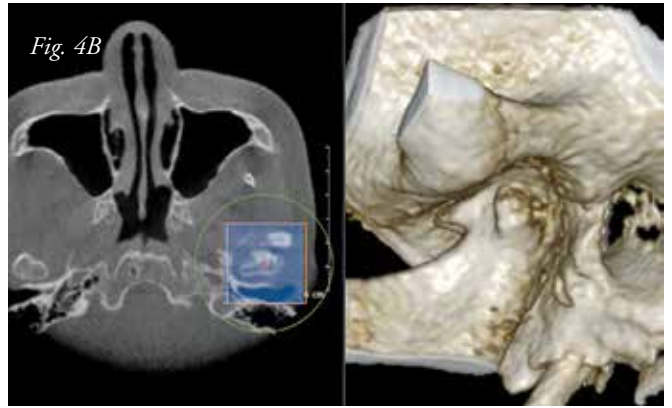
The full extent of the dilacerated root structure is not appreciated until we see a 3D color reconstruction in the coronal plane. We are viewing the tooth from the posterior in this image. This extraction would not be simple!

Case 4

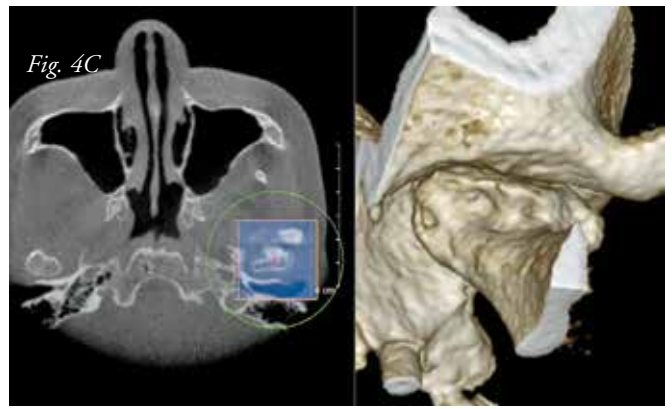
A 58-year-old Japanese woman said she had pain. Her dentist examined further and was able to see her TMJ complexes.



There appears to be a small osteophyte or "bird beak" on the anterior portion of the left TMJ condyle.



3D color reconstruction of the left condylar head verifies the suspected "bird beak." However the term "bird beak" is a holdover from the days of simple planar tomography in which cuts of approximately 3mm were taken of the condylar head. Cone beam 3D imaging is now able to clarify the true nature of the osteoarthritic change. This is seen in Figure 4C.



3D color reconstruction of the left condylar head shows the full extent of the change on the anterior surface of the condylar head. This change, also seen in other loader joints such as the knee, is termed "lipping."

Case 5

This 28-year-old male patient was assessed using cone beam 3D imaging because of his snoring and sleep apnea problems.

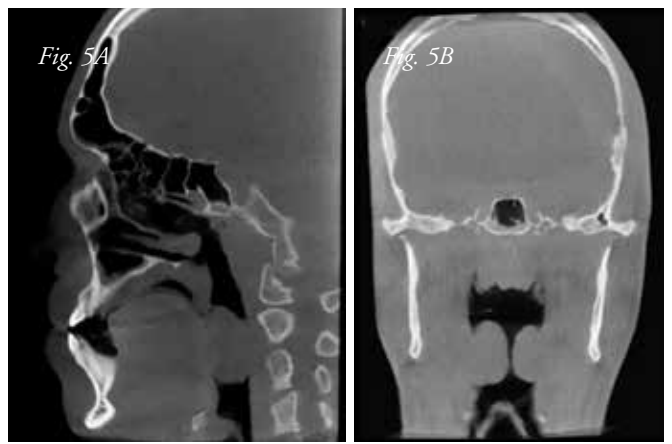


Figure 5A- A 2D grayscale sagittal view just to one side of the midline showing airway mass. Figure 5B - A reconstructed coronal image in thin slice showing grossly enlarged tonsils.

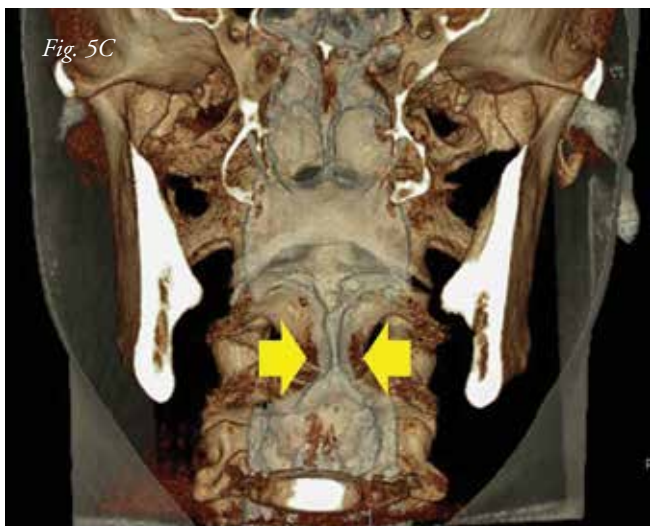

Fig. 5C
A color 3D coronal image reconstructed at approximately 20mm showing the narrowing of the airway from the tonsillar tissues (yellow arrows).

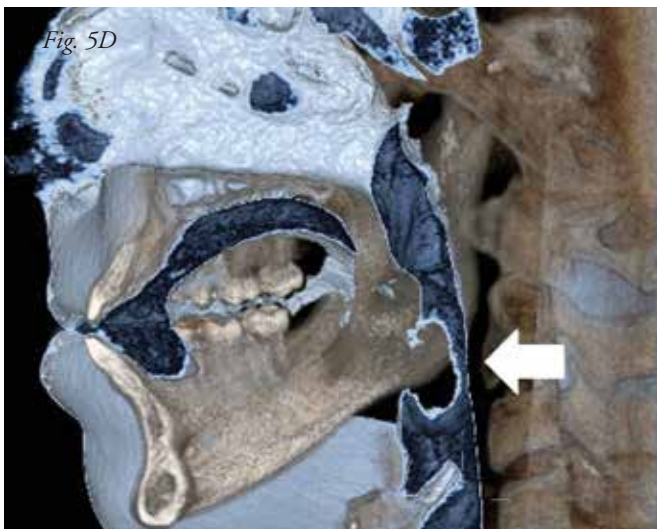


Fig. 5D
A color 3D sagittal image, reconstructed at approximately 20mm, showing the narrowing of the airway (white arrow). The airway itself can be measured linearly or volumetrically in the OnDemand 3D software.

I am still amazed at the power of the image processing which can be performed on the individual grayscale cone beam 3D image data set.

Conclusion

These are just a few of the more than 17,000 cases which I have seen and reported in the past six years. I am still amazed at the power of the image processing which can be performed on the individual grayscale cone beam 3D image data set. The images from the examples above would have been embedded in the reports for complete characterization of the problem(s) for which the referring dentist has responsibility. The report and the images truly help to make the clinical decision-making much easier for the dentist. If you adopt cone beam 3D imaging, that dentist could be you. ■

References

1. Miles DA: *Color Atlas of Cone Beam CT for Dental Applications* (title change), Quintessence Publishing Company, Inc., Hanover Park, IL, (2nd edition, December 2012).
2. Rottke D, Patzelt S, Poxleitner P and Schulze D: *Effective dose span of ten different cone beam CT devices. DMFR* (2013) 42(7).

Questions about cone beam? Ask them at Dentaltown.com/magazine.aspx.

Author Bio



Dr. Dale Miles, a diplomate of the American Board of Oral and Maxillofacial Radiology, has authored more than 130 peer-reviewed articles and six textbooks, including the best-selling cone beam textbook, *Cone Beam CT, Color Atlas of Cone Beam CT for Dental Applications* (Quintessence Publishing). He has a website for teaching dentists and staff about digital and cone beam imaging at Learndigital.net and a social network television channel called Interactiveimagingtv.com. Dr. Miles is in full-time practice of oral and maxillofacial radiology in Fountain Hills, Arizona, and is president of EasyRiter, LLC, which produces a simple CBCT report-generating software for the profession.