

The agony and ecstasy of buying cone beam technology

Part 2: The Ecstasy

Dale A. Miles¹

Abstract

Background: This is the second article in a two part series that presents additional decision considerations when purchasing a cone beam computed tomography (CBCT) machine for use in dental practice. **Methods:** The author, a Diplomate of the American Board of Oral and Maxillofacial Radiology, draws upon his personal experience from interpreting over 3,700 CBCT scans to provide general and technical information on a number of CBCT systems. **Results:** CBCT scan volumes, CBCT scan information, range of interest (ROI), field of view (FOV), multifunctionality, and potential liabilities are discussed by the author. **Conclusion:** When considering the acquisition of a CBCT machine, one should evaluate a number of factors to make an informed purchase. Failure to consider these factors may result in a dissatisfied buyer and potential liabilities.

Key words: Cone beam computed tomography, digital radiography, radiographic image enhancement

Introduction

In part one of this two part article series, "The Ecstasy," I presented introductory information on cone beam computed tomography (CBCT) machines, the wide array of applications made possible by the incredible variety of image output choices, and some decision considerations for helping you decide which cone beam device might best suit your

practice. In the second installment of this series, I will provide you with additional "decision points" to consider when selecting the appropriate machine or service for your practice and some of the realities of adopting this technology related to: **1)** The amount of information in each scan volume; **2)** The types of information in each scan; **3)** The potential liability accompanying your purchase.

Scan Volume Decisions

Initially, there was a marketing competition between companies that sold cone beam machines, with each making claims about the value of "large volume" machine advantages over "small volume" machines and vice versa.

¹ Dale A Miles, BA, DDS, MS, FRCD, Professor of Oral and Maxillofacial Radiology, Arizona School of Dentistry & Oral Health; Adjunct Professor, University of Texas Dental School, San Antonio, USA. Full-time practice, Oral & Maxillofacial Radiology, Fountain Hills, Arizona, USA.

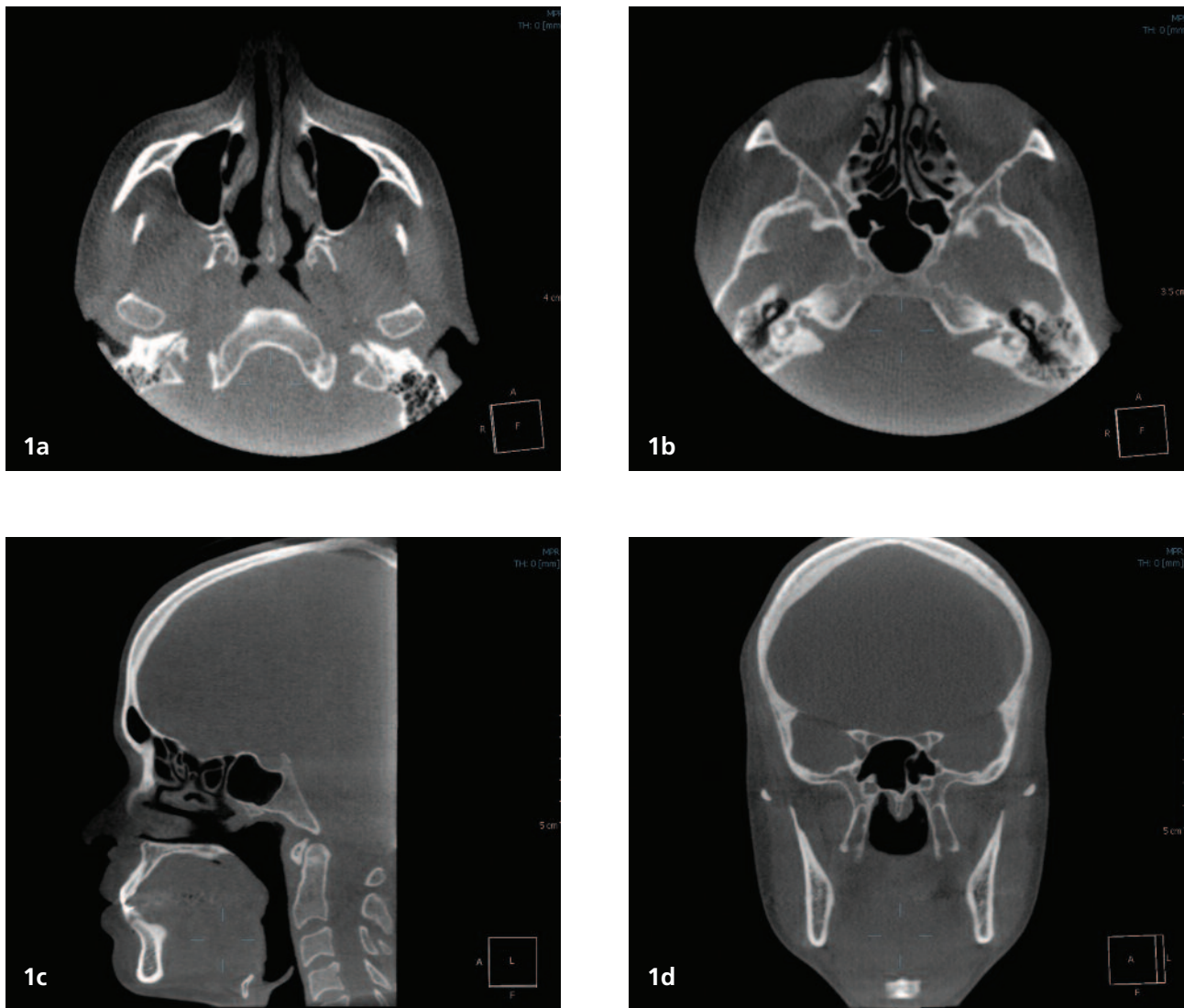


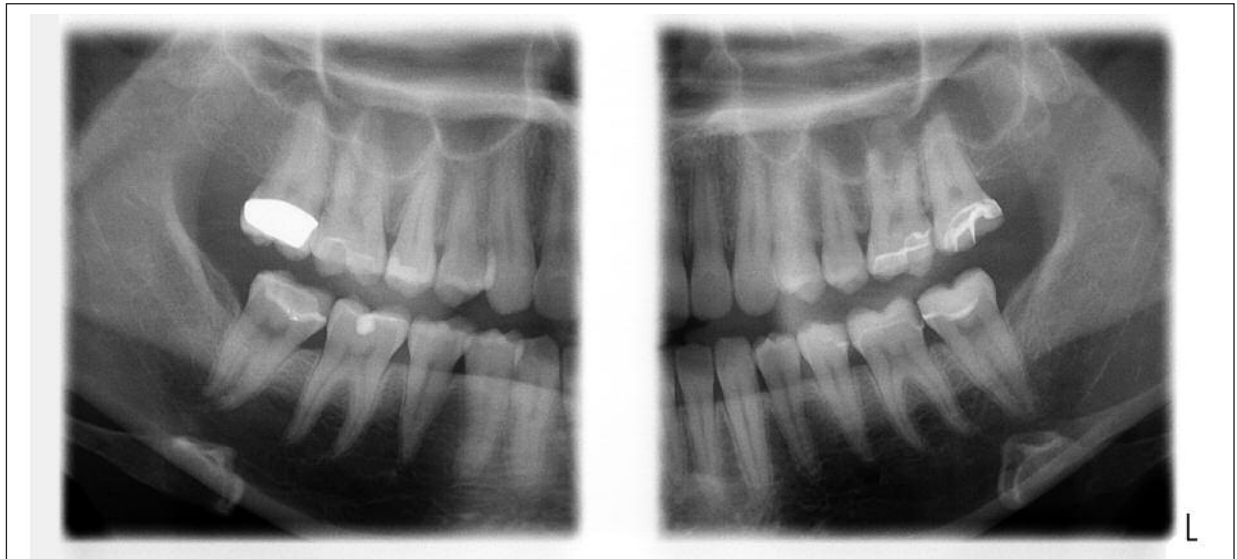
Figure 1: 1a. Axial slice of 346 slices at the level of the condylar head. 1b. Axial slice of the same patient slightly higher up in the scan at the level of the sphenoid sinus. 1c. and 1d. Sagittal and coronal slices through the sphenoid region.

Some claims, I feel, are valid, and some are not.

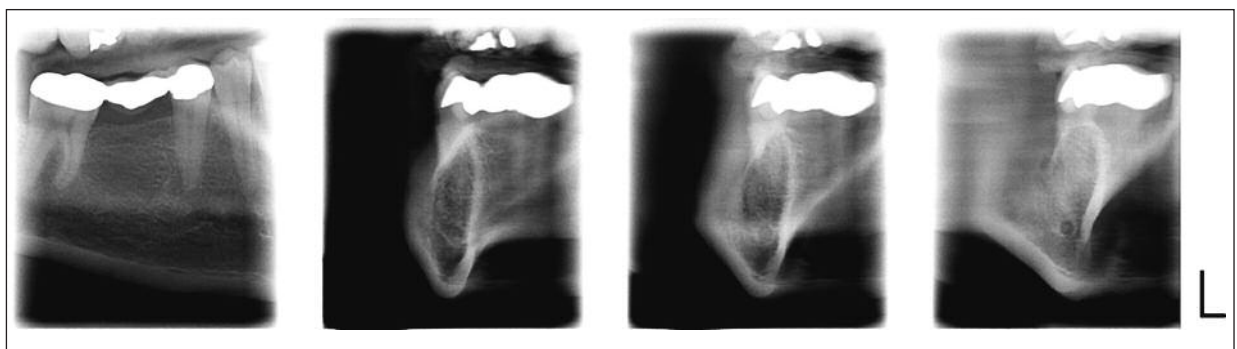
If you are an orthodontist and need to make measurements for various orthodontic analyses, you may require a large volume CBCT machine. Certainly, if the CBCT machine volume is 4cm x 4cm or less, for example, a small volume machine would not suffice if you do not have a cephalometric unit in addition to your cone beam machine. You would have to select a machine like the Imaging Sciences i-CAT (Hatfield, PA) or similar large Field of View (FOV) machine to capture your Region of Interest (ROI). Figure 1 shows some image areas captured by a "large" FOV machine.

However, if you had a machine that was *multifunctional*,

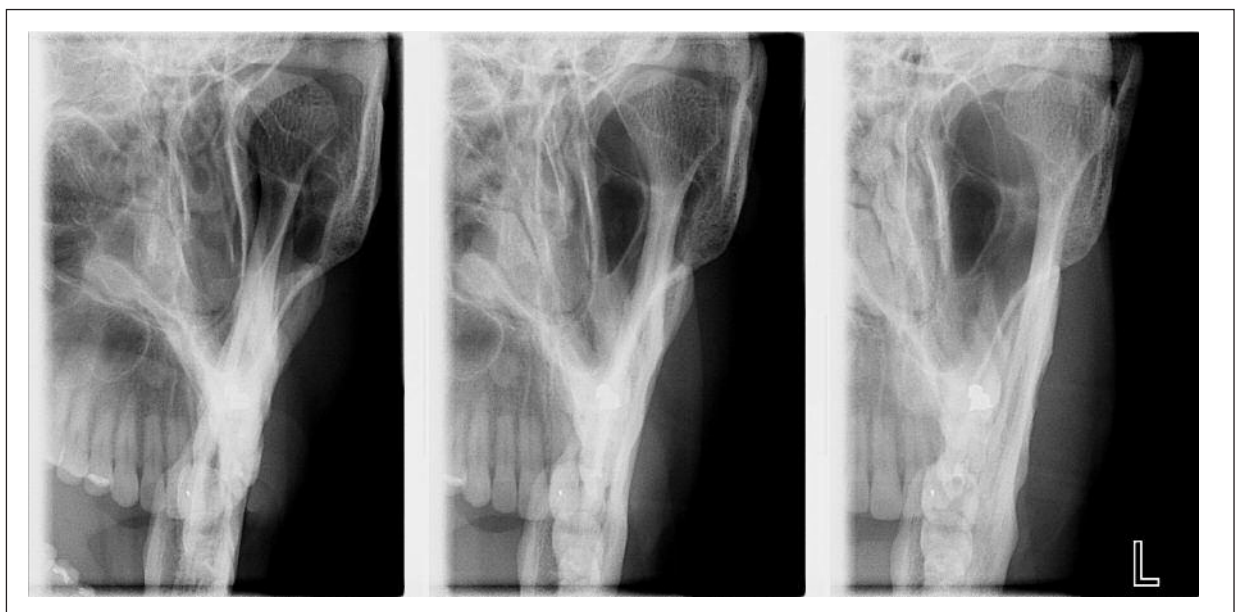that is, one that can deliver a cone beam data set or volume, even if only 8cm x 8cm, and still retain the panoramic and cephalometric capability, then a machine like the Planmeca Pro-Max (Roselle, IL), the eWoo Picasso (Va-tech, Seoul, Korea) or Morita Veraviewepocs3D (Kyoto, Japan) could be advantageous. Initially, Planmeca was the only multifunctional machine and currently remains the only "upgradeable" x-ray machine on its existing platform. In addition to its panoramic and cephalometric capabilities, the ProMax CBVT 3D machine can also perform bitewing and periapical-like projections as well as selectable tomographic views of the TMJ and sinus regions. This is because of its unique technology: *SCARA – Selectively Compliant*



2a



2b



2c

Figure 2: Images acquired with SCARA technology. All images taken on a panoramic machine (ProMax, Planmeca USA, Inc, Roselle, IL). 2a. "Panoramic bitewing" radiograph; 2b. Implant cross-sectionals; 2c. Tomographic images of the left TMJ condyle.

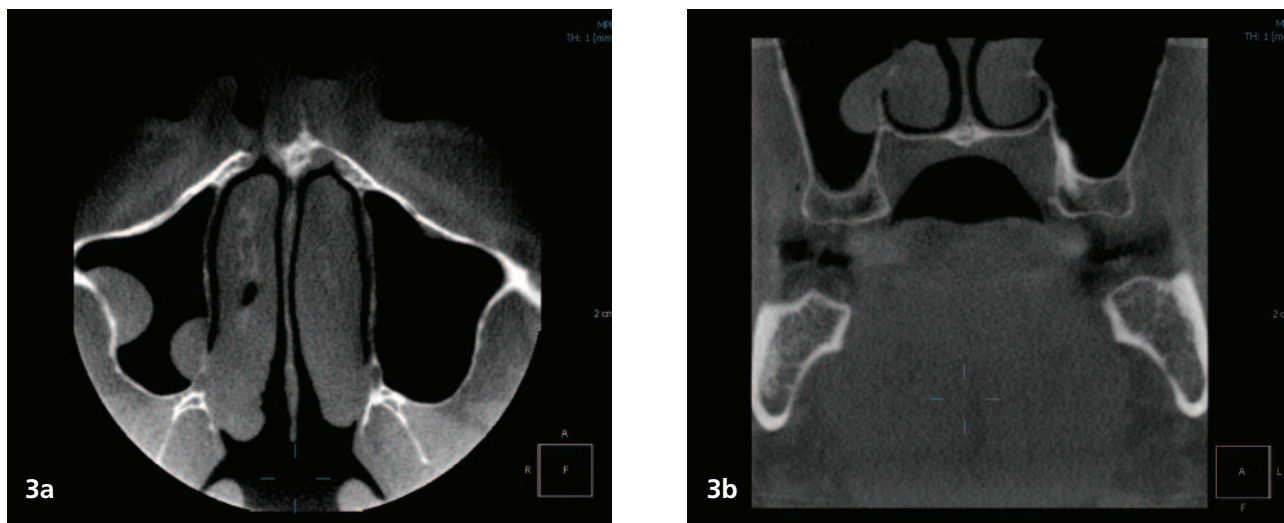


Figure 3: 3a. Axial slice of 500 slices at the level of the mid maxillary sinus showing 2 mucous retention cysts. 3b. Coronal slice near a posterior implant site showing the more medial mucosal lesion in the same patient possibly communicating with the inferior turbinate.

Articulating Robotic Arm. This SCARA technology (figure 2), coupled with a C-arm mounted on the top of the machine, is a patented “one-of-a-kind” device in the dental x-ray industry. The description of this technology is beyond the scope of this article, but its concept is what allows for all of the following, making this machine the most “multi-functional”: 1. True panoramic (not reconstructed from software); 2. True cephalometric image; 3. Tomographic views (TMJ, sinus and implant if desired); 4: Bite-wing views (large enough to see all periapices and at about 6 lp/mm); 5: Orthogonal panoramic view to see interproximal bone levels.

This concept of “multifunctionality” can be confusing with some claiming you can replace all dental imaging with cone beam technology. As in medicine, dentists need to preserve several types of imaging modalities and choices to assist their diagnostic tasks. Medicine certainly does not use or expect one radiographic imaging modality to cover all diagnostic tasks. Accordingly, the medical profession uses plain radiographic images, CAT scans, PET scans, magnetic resonance imaging (MRI), ultrasonography, and nuclear medicine scanning to assess their patient’s problems. Dentistry is gradually moving in a similar direction, especially with cone beam technology and cone beam “multifunctional” machines.

To confound your decision-making, many “large volume” manufacturers claim that “you can do ALL of your imaging ONLY with a cone beam machine.” In my opinion, this is not true and should never be considered because of two factors I have previously discussed at length: namely, increased dose

to children and reduced productivity required for reconstructing an image like the panoramic. 1-3 A perfect example of this is monitoring the status of deciduous and permanent successor teeth in young children. When performing routine exams such as these, you must carefully weigh the risks of additional radiation exposure in obtaining CBCT volume sets when a simple panoramic image would suffice.

Figure 3 shows some “small” FOV images and images from multi-functional machines.

In these examples, the dentist, in most cases, would be skilled enough to interpret the antral findings. If nothing else, he or she would describe the lesions they found and refer the patient for an otolaryngologic evaluation. A simple description of the changes seen would suffice as long as it was accompanied by informing the patient and referring that patient to a specialist or back to their primary care physician for further evaluation. It is harder to see these changes in the first case/example (Figure 1) because of the increased area of coverage. Remember, you are not looking a single image, but rather 300-500+ slices in 3 planes. The examination of these volumes, large or small, takes time.

With respect to the “large vs. small debate”, there seems to be a compromise on the horizon. Large volume manufacturers are moving towards a selectable FOV so that the operator can select a smaller region to fit the diagnostic task. Small volume manufacturers, on the other hand, appear to be getting ready to offer machines with large FOVs to attract customers like orthodontists who require larger areas for cephalometric analyses.

Table 1: Common Reportable Findings on CBCT Scans

1.	Paranasal sinus disease such as mucous retention cysts, chronic sinusitis and blocked ostia
2.	Enlarged adenoid and tonsillar tissues
3.	Tonsilloliths
4.	Deviated nasal septae and concha bullosa* (Figure 4)
5.	Calcified, elongated stylohyoid ligaments
6.	Osteoarthritic changes on TMJ condyles
7.	Osteoarthritic changes on cervical vertebrae
8.	Missed dental conditions such as palatal root lesions, bone loss and implant perforations (usually because 3D imaging was not used)
9.	Inferior alveolar nerve proximity to and contact of impacted third molars

Table 2: Significant Findings (number of cases in parentheses)

1.	Throat masses (4)
2.	Vertebral tumors (2)
3.	Fungus balls (aspergillosis), sphenoid sinus (2)
4.	Odontogenic cysts and tumors (6-10)
5.	Calcified plaques and medial arterial calcinosis (approximately 30)
6.	Oro-antral fistulae (more than 5)
7.	Implant perforations (more than 20)
8.	Cranial tumors (2)

The Types of Information in Each Scan

So what exactly is found in these scans? Back in late 2006, I published an article describing the findings of the first 381 cone beam volumetric cases I examined for various radiology laboratory services.⁴ Even now, after interpreting almost 4,000 cases to date, I am impressed with the amount of “reportable pathology” in these data volumes. Table 1 lists the most common findings I have seen on the majority of scans I review while Table 2 lists some of the more significant findings that I have reported over the course of my career. It is important to evaluate the entire data volume. The number of significant and reportable findings I have seen over the years support this concept.

Potential Liability

One of the biggest misconceptions in the dental profession is who “owns” the liability if a significant finding is missed during interpretation of a CBCT scan. Some of this confusion can be attributed to a so-called “mock trial” held at the 108th annual session of the American Association of Orthodontists in 2008. Following the session of the “Doctor’s Risk Management Program”, Ms. Elizabeth Franklin, a claims manager for the AAOIC (American Association of Orthodontists Insurance Company) wrote the following:

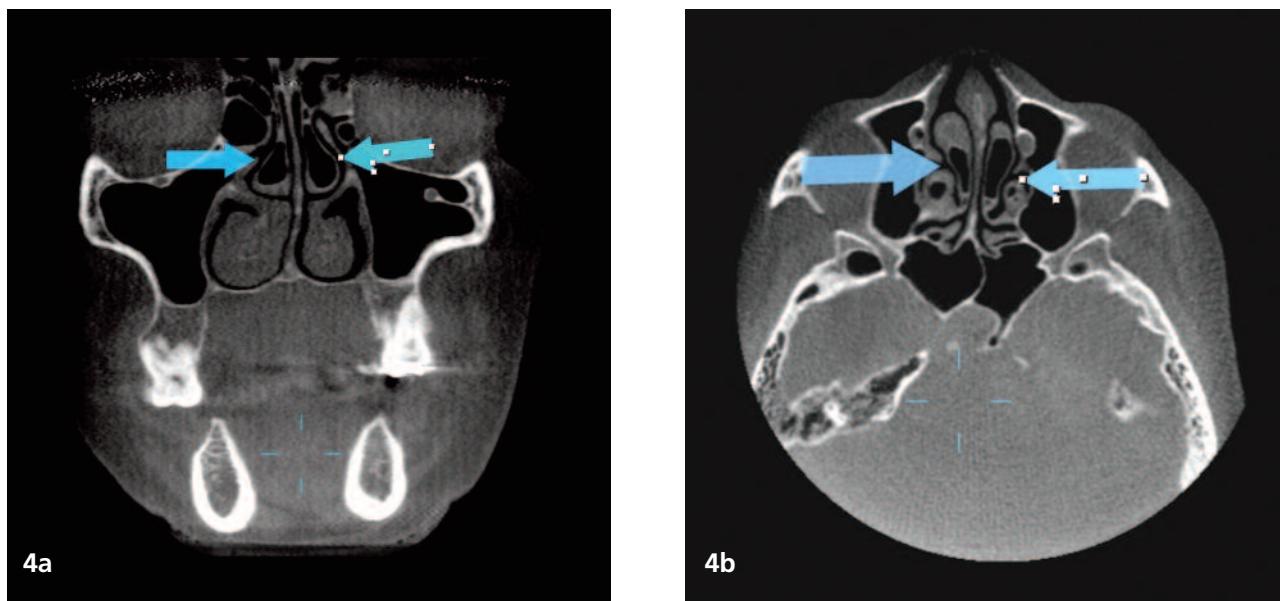


Figure 4: An example of the anomaly "concha bullosa" in the middle turbinates.

***Concha bullosa:** Aeration of the middle turbinate, termed "concha bullosa," is a common anatomical variant of intranasal anatomy. Of 320 patients evaluated for sinus disease with coronal CT, 34% had concha bullosa on at least one side. The overall incidence of inflammatory disease in the ostiomeatal complex in these symptomatic patients was not different between those with and without concha bullosa. However, there were many cases in which an abnormally large middle turbinate appeared to obstruct the ostiomeatal complex causing secondary infection of the ethmoid, frontal, and maxillary sinuses. Obstruction of drainage of the concha bullosa itself can lead to mucocele formation. Furthermore, the presence of a concha bullosa has important implications for the technique of endoscopic surgery used in the management of the sinus disease.

"Cone-beam scans are a relatively new form of imaging available to the orthodontists to enhance patient treatment. Many orthodontists, however, are not trained to read three dimensional scans. If the scans are not read accurately and thoroughly, and incidental findings are missed, the orthodontist can assume a greater liability for failure to refer.

*To protect from this exposure, the scans should be read by a trained practitioner."*⁶

This is prudent advice. In a recent article by trial lawyer Mr. Kevin Henry,⁷ at the 1st International Congress on 3-D Dental Imaging, California litigation attorney Arthur Curly, who specializes in medical and dental malpractice, informed dentists that:

"Dentists and team members are not licensed to treat medical problems or any other issues outside of the oral cavity, so they are also not licensed to diagnose

conditions outside the oral cavity that are outside the scope of their dental practice. Therefore, dentists can recommend 3-D imaging as an option without fears that they could be liable for diagnosing everything seen on the image. They are only responsible for those areas that are within the scope of their practice, dentistry: jaws and oral cavity."

Unfortunately, some dentists have taken this to mean that they don't have to look at the data volume except as it pertains to their region of interest or the specific task for which they acquired the volume. If you read the assertion by Mr. Curly, someone has to look at all of the data. The prevalence of "occult pathology" is just too great.

For comparison, let's consider that you have had a preliminary chest x-ray taken to examine your heart for enlargement or hypertrophy of the muscle. Do you really think your physician or the radiologist would fail to look at the lung field as well in that chest film? By the same analogy,

you would never consider examining only half of a panoramic radiograph because only one lower third molar was thought to be present. Accordingly, why would you think that no one has to look at the entire cone beam data volume when only an implant site is being assessed? If the patient was harmed because you didn't look at the full data volume or have someone look at the data for you, it is my firm opinion that you may be facing a future lawsuit.

In the Spring issue of the North Carolina State Board of Dental Examiners Newsletter, 8 Dr. Clifford Feingold, the editor, stated:

"It is the Board's understanding that some CBCT manufacturers emphasize that the machine may be used to evaluate a single region of interest (orthodontic planning for example), and that patient release/consent forms will absolve you from all responsibility from any outside specific narrowly tailored usage. This, of course, is a legal rather than a medical question and the Board urges you to consult your legal counsel for advice before risking exposure to potential liability. However, you should always remember that the Board views the use of CBCT under the rules applicable to radiographs. Therefore, if you acquire a volume of data, you should be able to interpret the data for a complete and accurate diagnosis."

This, to me as a dentist and a radiologist, seems like a prudent approach. Just because the technique is new and novel, at least for dentistry, why would we NOT be responsible for interpretation of the data?

The first is that they are not comfortable with all the anatomy and potential pathology which may reside in the volume data. This is a legitimate concern and many colleagues have sought out specialists in oral and maxillofacial radiology to help them. The second is that they do not want to "pay" the added cost, or have the patient pay an "extra fee" to have a specialist look at the volume, because it might make the case "too costly" for the patient and the dentist might lose the anticipated procedure fee. This is self-serving and again, in my opinion, irresponsible behavior on the part of a dentist.

I even know of a colleague who has a patient sign a "refusal" document to have the cone beam volume read by a specialist. Regarding "informed consent" and "informed refusal" of care or treatment, a succinct explanation is presented in the May-June 2007 issue of The Reporter, a publication of the Texas Medical Liability Trust (TMLT). In this

issue, Ms. Jane Holeman, vice-president of Risk Management for the TMLT states the following:⁹

"Implicit in and intrinsic to the concept of consent for treatment is the option of refusal. In Cruzan v Director, Missouri Department of Health, the U.S. Supreme Court ruled that all U.S. citizens have a constitutional right to refuse un wanted therapy, a right residing in the due process clause of the 14th amendment. Authorized surrogates can exercise this right of refusal on behalf of the incapacitated patients they represent. This right of refusal pertains to all therapies, including life-sustaining therapies and artificial hydration and nutrition, without which patients will die." All patients have the right, after full disclosure, to refuse medical treatment. This can include patients who decline medication, routinely miss office visits, defer diagnostic testing, or refuse hospitalization. Physicians are then pro hibited from proceeding with the intervention. "Problems arise, however, when the patient or the patient's family later argues that they were not given enough information to make an informed decision, or that the patient lacked the capacity to make the decision..."

The final part of this statement holds the key to this dilemma. How can a patient be expected to make an informed decision before they have all the information? If the scan volume is not interpreted and the dentist lacks ANY information about potential diagnoses and problems which might be in the x-ray data, that is the "occult pathology", how can the dentist say that he/she has fully informed the patient? The very thought that they've received informed consent from the patient, a dental and medical necessity, before all the information is evaluated and known is absurd. How can the patient give or sign their "informed refusal" without having knowledge of all of the information in the x-ray?

Conclusions

Despite my rather sobering comments about the "Agony" of cone beam imaging, the interest, use, and adoption of this modality is welcomed by the dental profession. We benefit by better decisionmaking information, our patients benefit by more precise surgical placement of implants and better assessment of orthodontic, TMJ, and sinus problems in addition to suspected and unsuspected pathology. We can expect improvement in hardware, software, detectors and knowledge as they relate to this impressive and much

needed technology. In the end, we can continue to bask in the “Ecstasy” of Cone Beam Imaging, because it truly helps us all: both patient and clinician.

Disclosure

The author reports no conflicts of interest with anything mentioned within this article.

This article was previously published in The Journal of Implant and Advanced Clinical Dentistry.
www.JIACD.com

References

1. Miles D, Danforth R. A Clinician’s Guide to Understanding Cone Beam Volumetric Imaging. Academy of Dental Therapeutics and Stomatology Special Issue 2007; 1-13.
2. Miles D. The Future of Dental and Maxillofacial Imaging. Dent Clin N Am 2008; 52(4): 917–928.
3. Miles D. Color Atlas of Cone Beam Volumetric Imaging for Dental Applications. Quintessence, Ch. 4-14 (pp 47-303), 2008.
4. Miles D. Clinical Experience with Cone-Beam Volumetric Imaging: Report of Findings in 381 cases. US Dentistry 2006; 1(1): 39-42.
5. Zinreich S, Mattox D, Kennedy D, Chisholm H, Diffley D, Rosenbaum A. Concha bullosa: CT evaluation. J Comput Assist Tomogr 1998; 12(5): 778-84.
6. Franklin E. “Doctor’s Risk Management Program.” 108th annual session of the American Association of Orthodontists. Denver, Colorado: May 2008.
7. Henry K. 10 tips from a trial lawyer. Dent Economics 2008; 98 (6).
8. Feingold C. Cone Beam Imaging. The Dental Forum, NC State Board of Dental Examiners Spring 2007.
9. Brockway L. When Patients Decline Treatment: Informed Refusal. The Reporter, Texas Medical Liability Trust; May-June 2007.